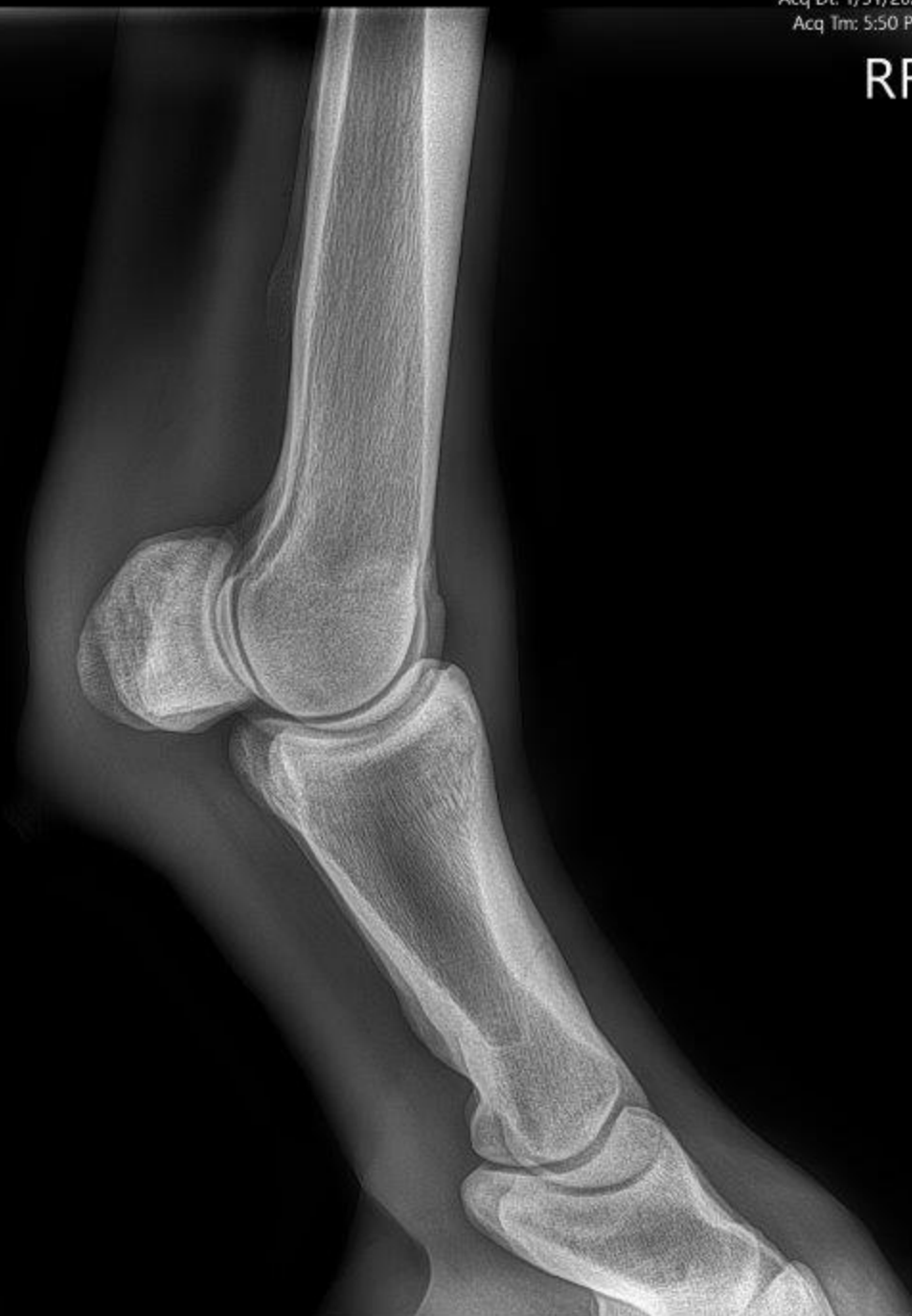

Tamba_Guillaume
Img: 19
Anatomy: Fetlock
View: LAT
La: RF

Vet Rec:
EL DES BLES, FERRYMAN
Equine
Acq Dt: 1/31/2022
Acq Tm: 5:50 PM

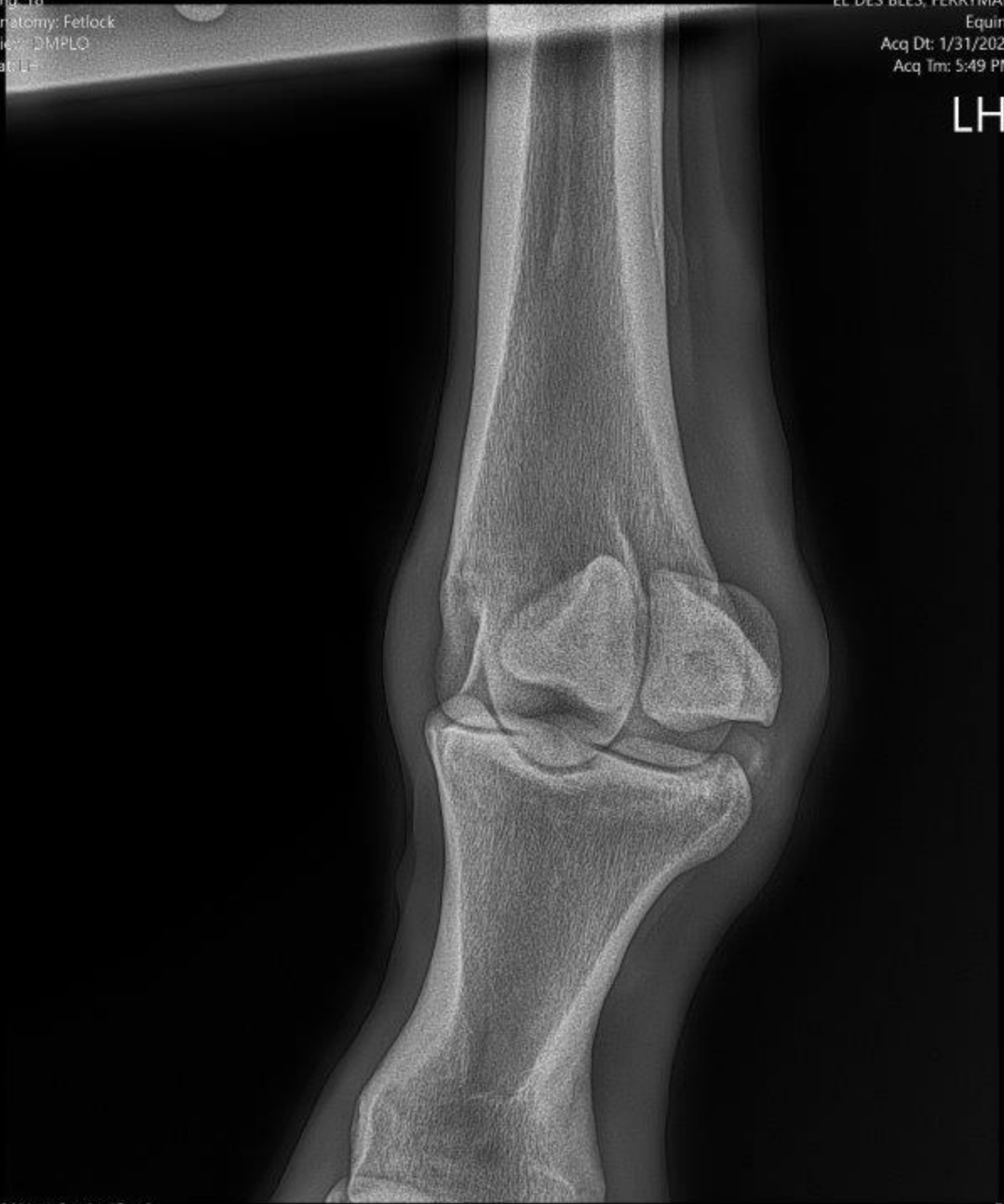RF



Tamba_Guillaume
Img: 18
Anatomy: Fetlock
View: DMPLO
Lab: LH

Vet Rec:
EL DES BLES, FERRYMAN
Equine
Acq Dt: 1/31/2022
Acq Tm: 5:49 PM

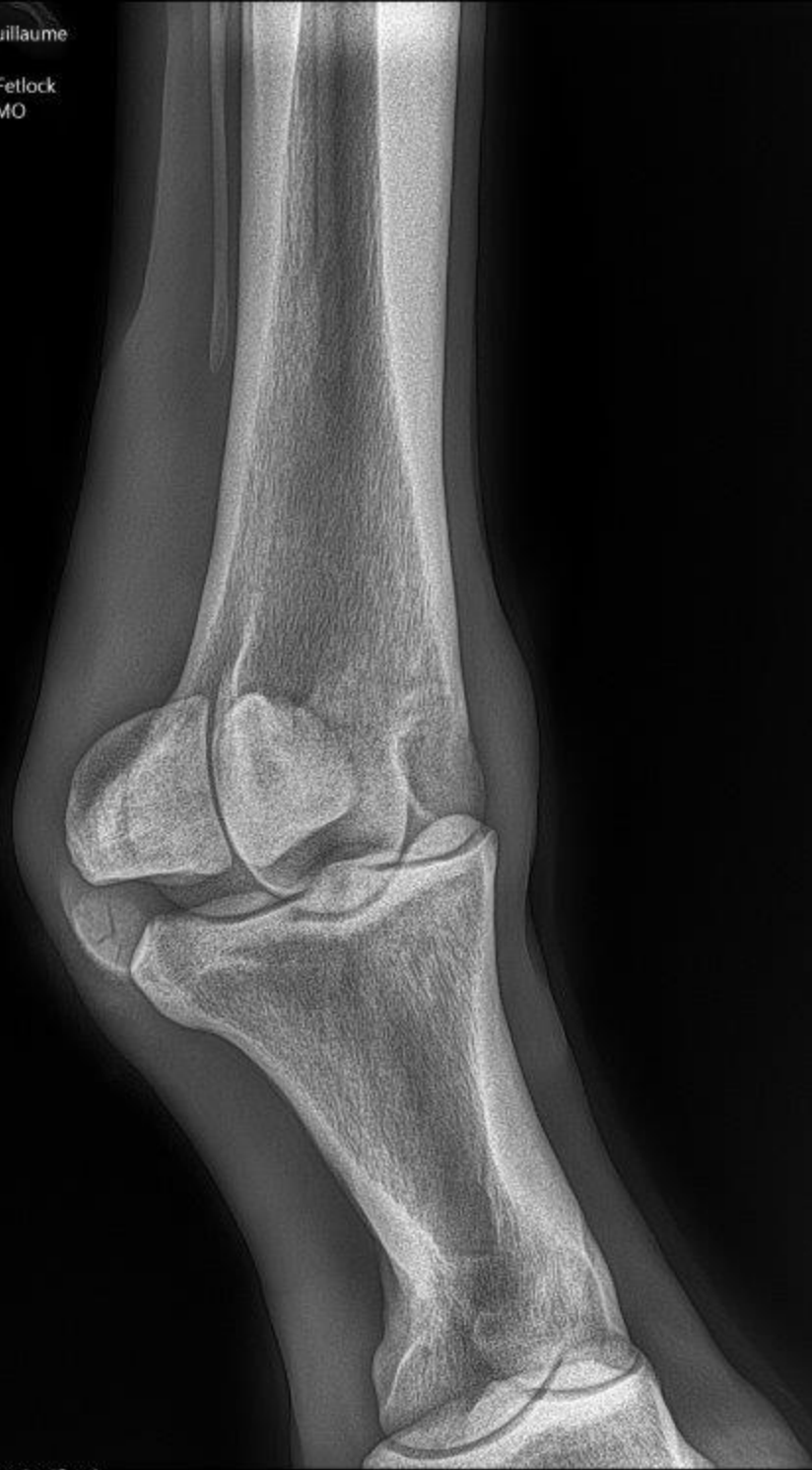LH



Tamba_Guillaume
Img: 17
Anatomy: Fetlock
View: DLP MO
Lat: LH

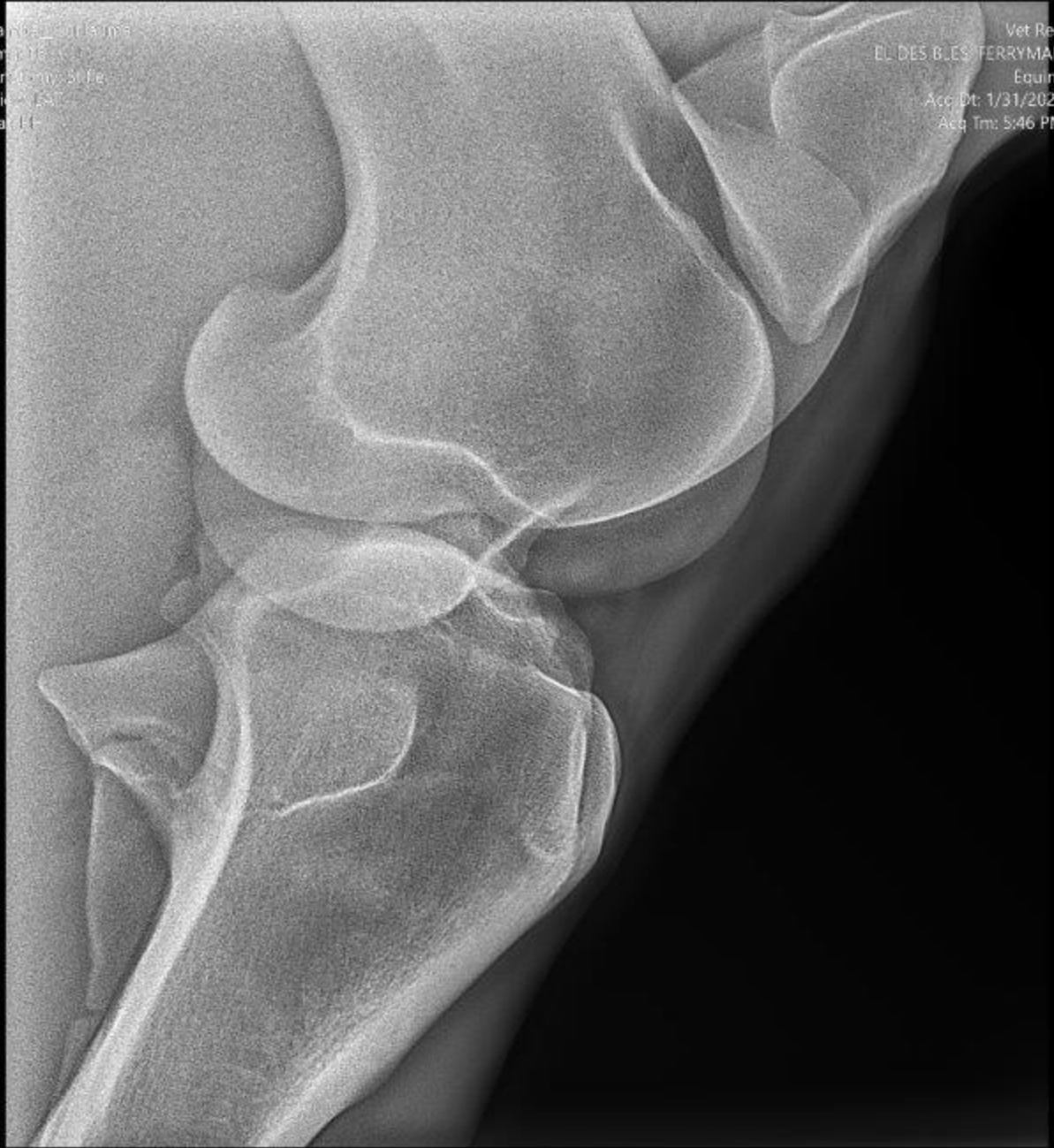
View Rec:
EL DES BLES, FERRISSAN
Equine
Acq Dt: 1/31/2022
Acq Tm: 5:41 PM

LH



Ta No 111115115115
Im 111115115115
Ar 111115115115
Vi 111115115115
La 111115115115

Vet Rec:
EL DES BLES FERRYMAN
Equine
Acc Dt: 1/31/2022
Acq Tm: 5:46 PM

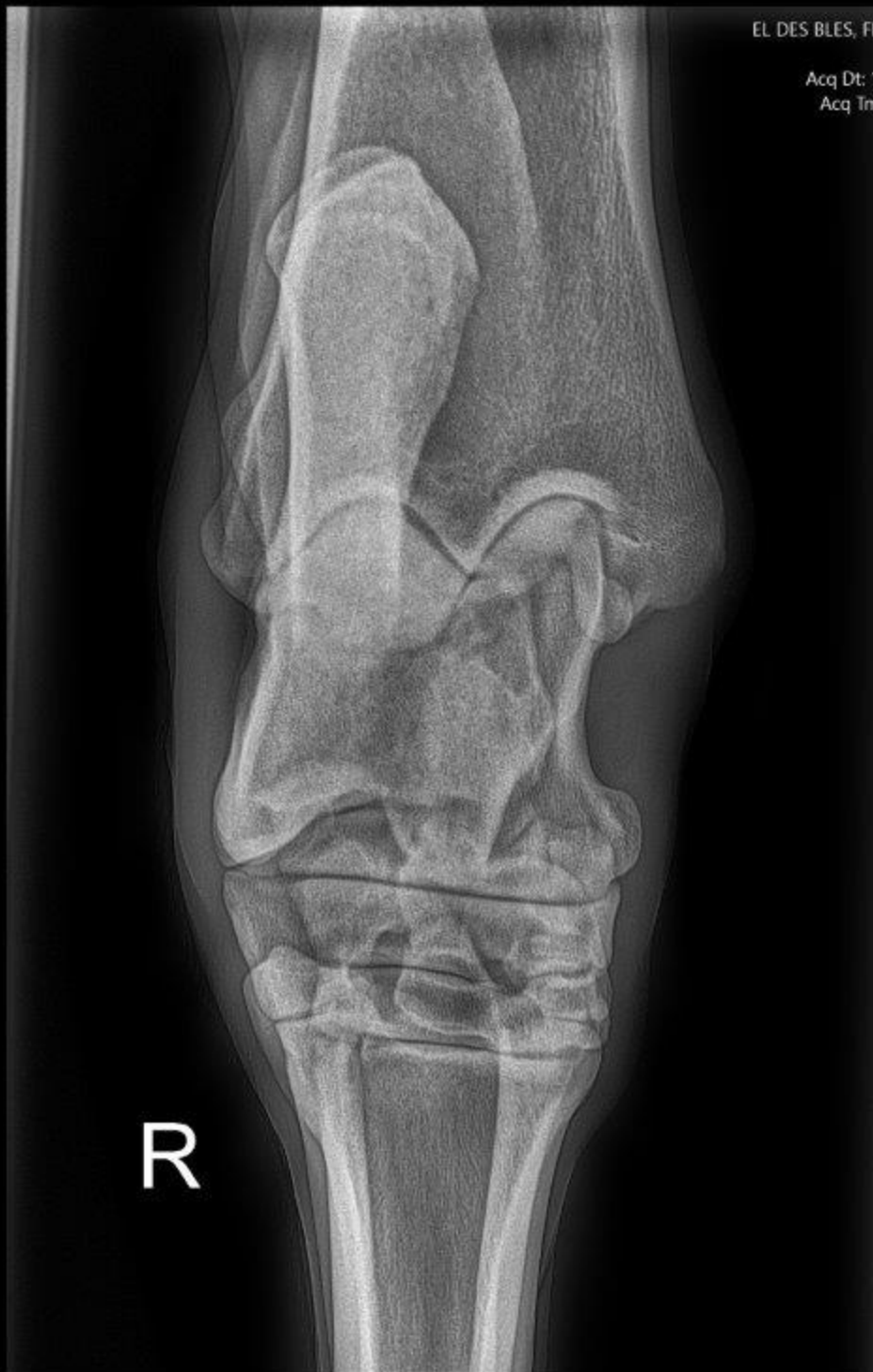

RH

Tamba_Guillaume
Img: 15
Anatomy: Tarsus
View: DP
Lat: RH

Vet Rec:
EL DES BLES, FERRYMAN
Equine
Acq Dt: 1/31/2022
Acq Tm: 5:46 PM

RH



R

Tamba_Guillaume

Img: 14

Anatomy: Tarsus

View: PA

Lat: RI

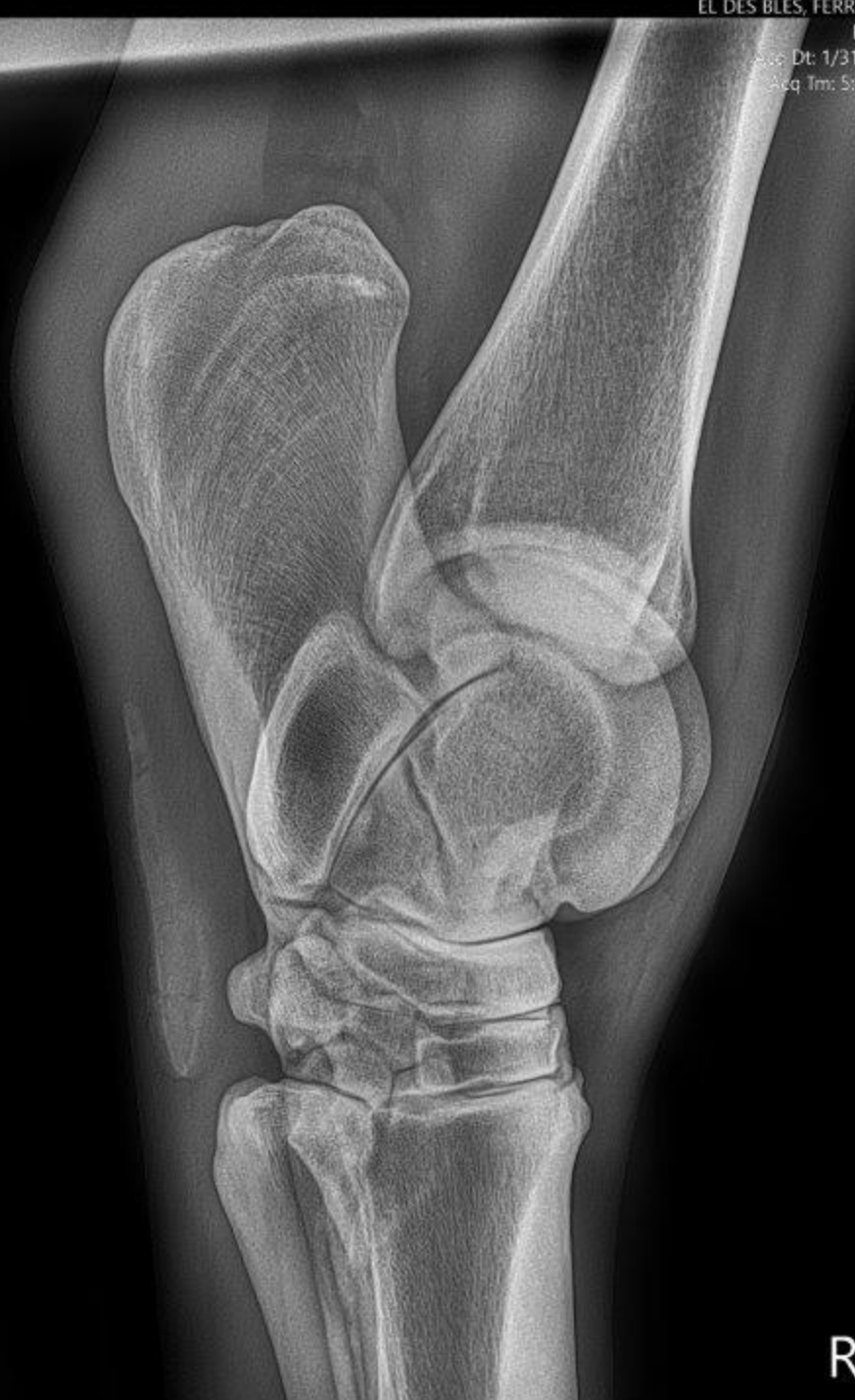Vet Rec:

EL DES BLES, FERRYMAN

Equine

Acq Dt: 1/31/2022

Acq Tm: 5:46 PM

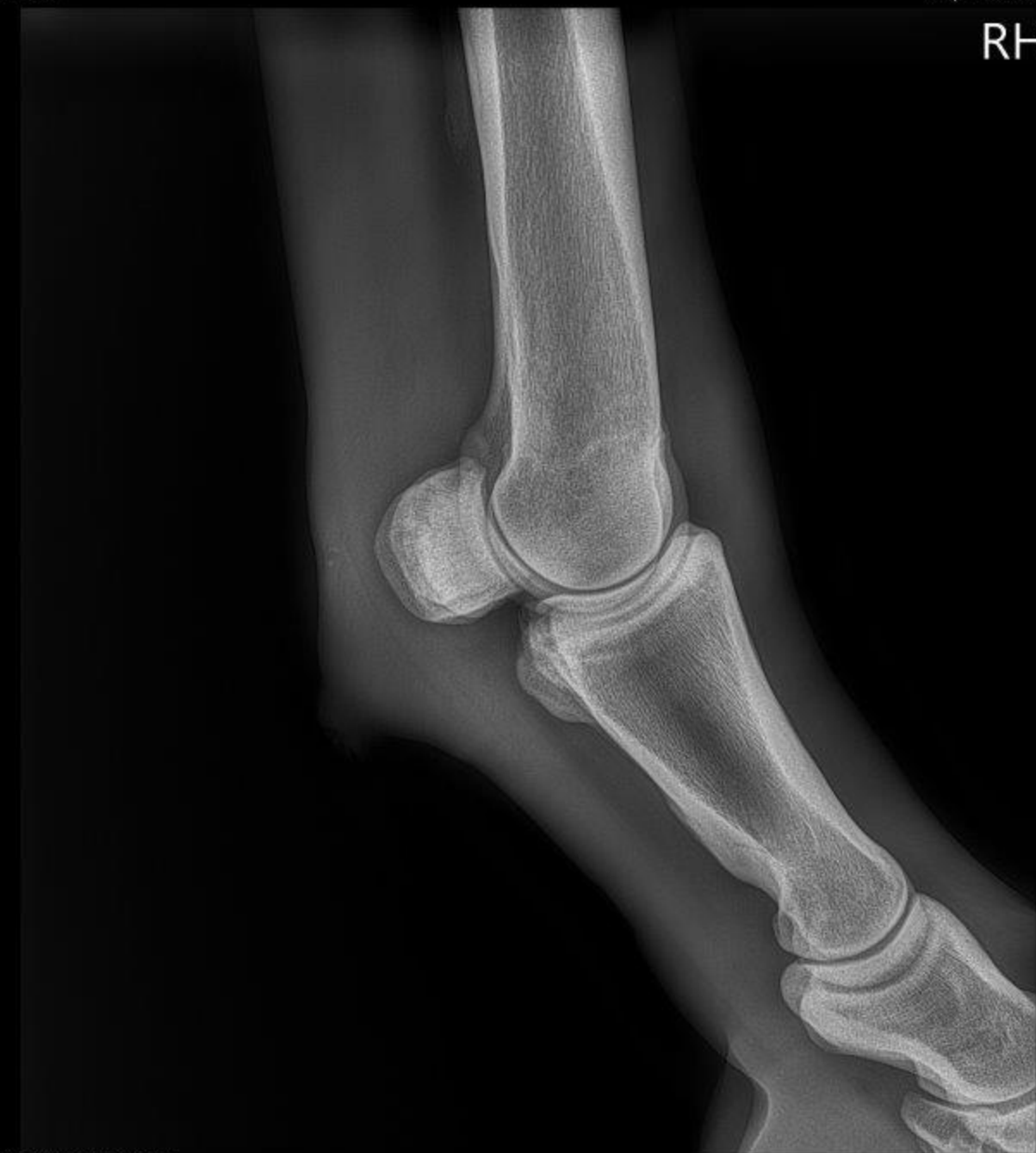

RH

Tamba_Guillaume
Img: 13
Anatomy: Fetlock
View: LAT
Lat: RH

Vet Rec:
EL DES BLES, FERRYMAN
Equine
Acq Dt: 1/31/2022
Acq Tm: 5:45 PM

RH



76 kVp 1.6 mAs 15 mA

DX

Tamba_Guillaume
Img: 12
Anatomy: Fetlock
View: DP
Lat: RF

Vet Rec:
EL DES BLES, FERRYMAN
Equine
Acq Dt: 1/31/2022
Acq Tm: 5:45 PM

RF

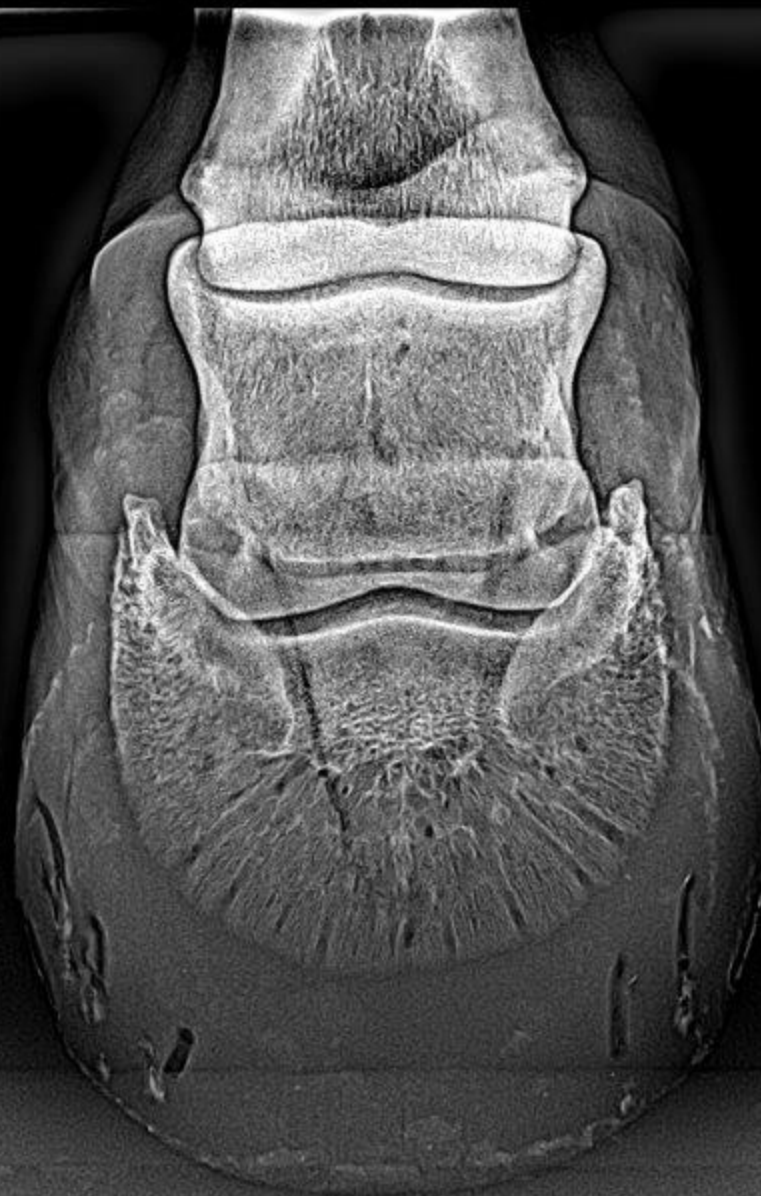R

A dorsal view radiograph of the right fetlock joint. The image shows the distal radius and ulna at the top, the two sesamoid bones in the middle, and the distal carpal bones at the bottom. The joint space is clearly visible between the bones. The image is labeled 'R' on the left side and 'RF' in the top left corner.

Tamba_Guillaume
Img: 10
Anatomy: Navicular
View: DP
Lat: RF

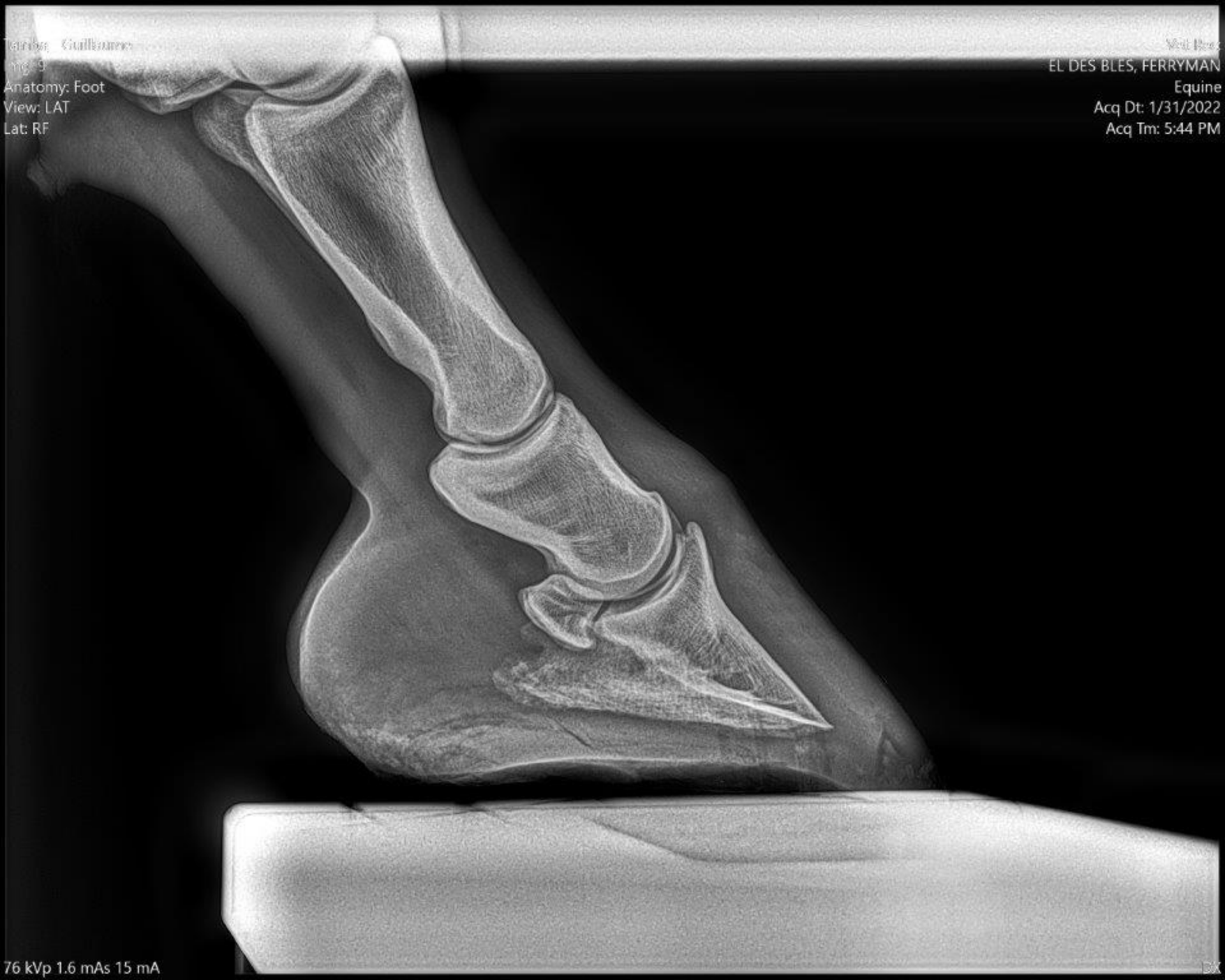Vet Rec:
EL DES BLES, FERRYMAN
Equine
Acq Dt: 1/31/2022
Acq Tm: 5:45 PM

R



Tarbo, Guillaume
img 9
Anatomy: Foot
View: LAT
Lat: RF

Stal, Hans
EL DES BLES, FERRYMAN
Equine
Acq Dt: 1/31/2022
Acq Tm: 5:44 PM



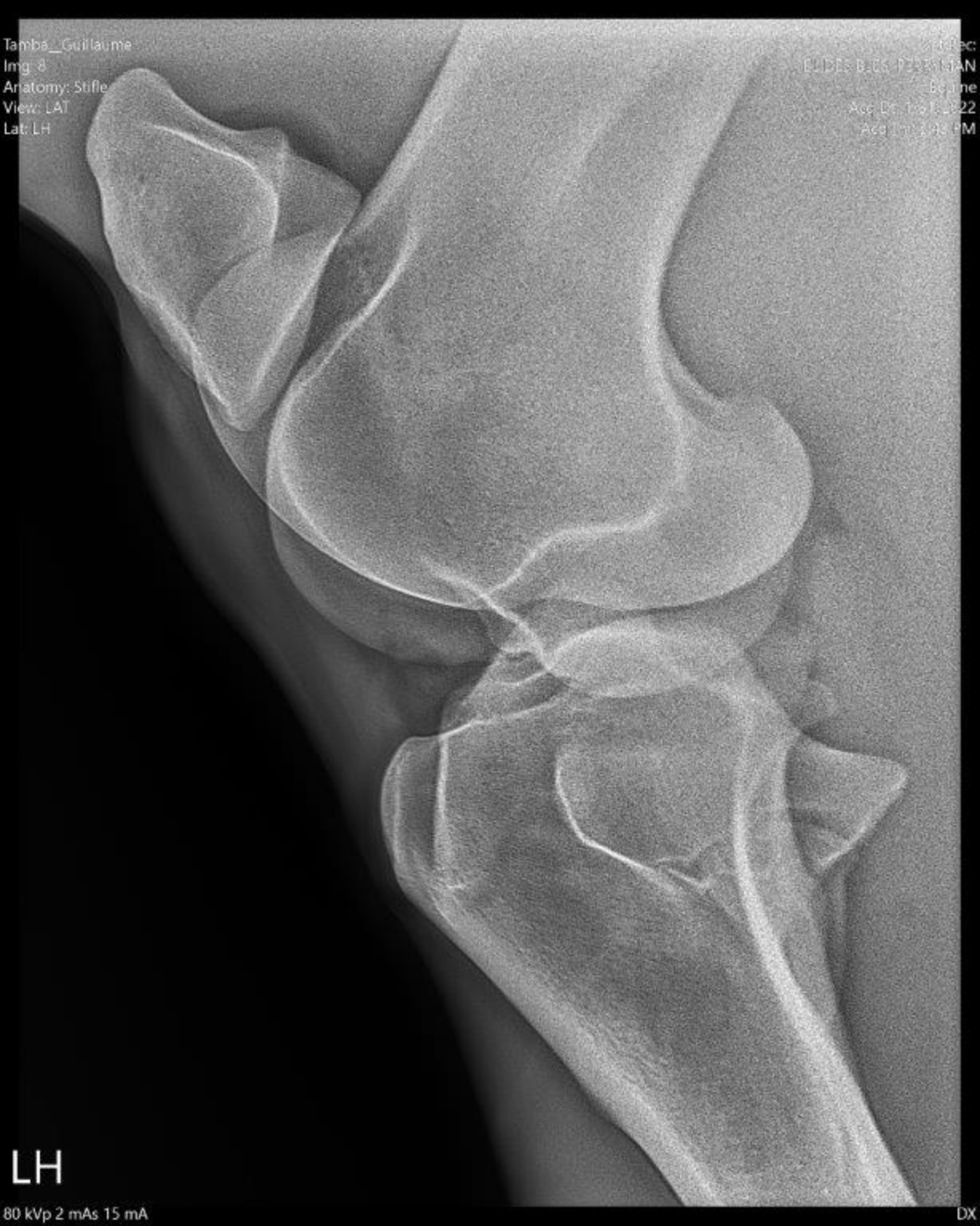Tamba_Guillaume
Img: 8
Anatomy: Stifle
View: LAT
Lat: LH

2018 Dec
ELIOS-BUS-PTERMAN
2018 Dec
Acq. Dr. 1/8/18/22
Acq. Dr. 1/8/18/22

LH

80 kVp 2 mAs 15 mA

DX

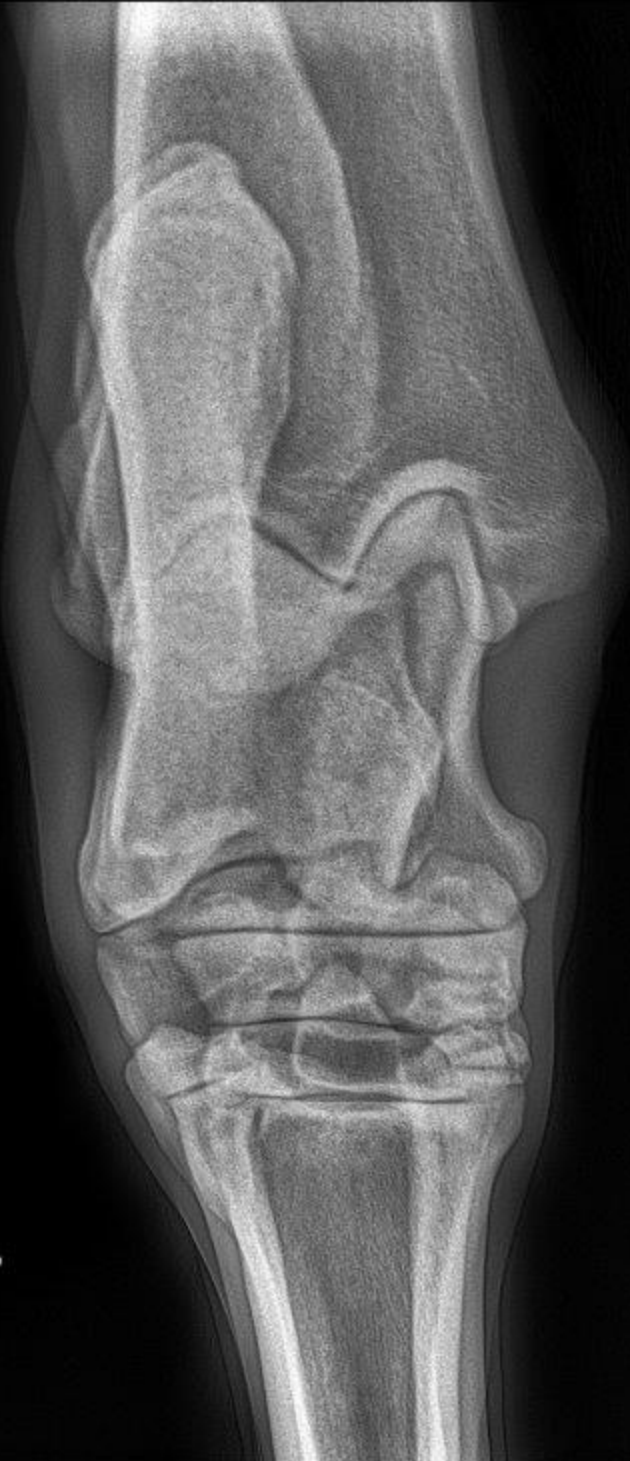

Tamba_Guillaume
Img: 7
Anatomy: Tarsus
View: DP
Lat: LH

Vet Rec:
EL DES BLES, FERRYMAN
Equine
Acq Dt: 1/31/2022
Acq Tm: 5:43 PM

LH

L



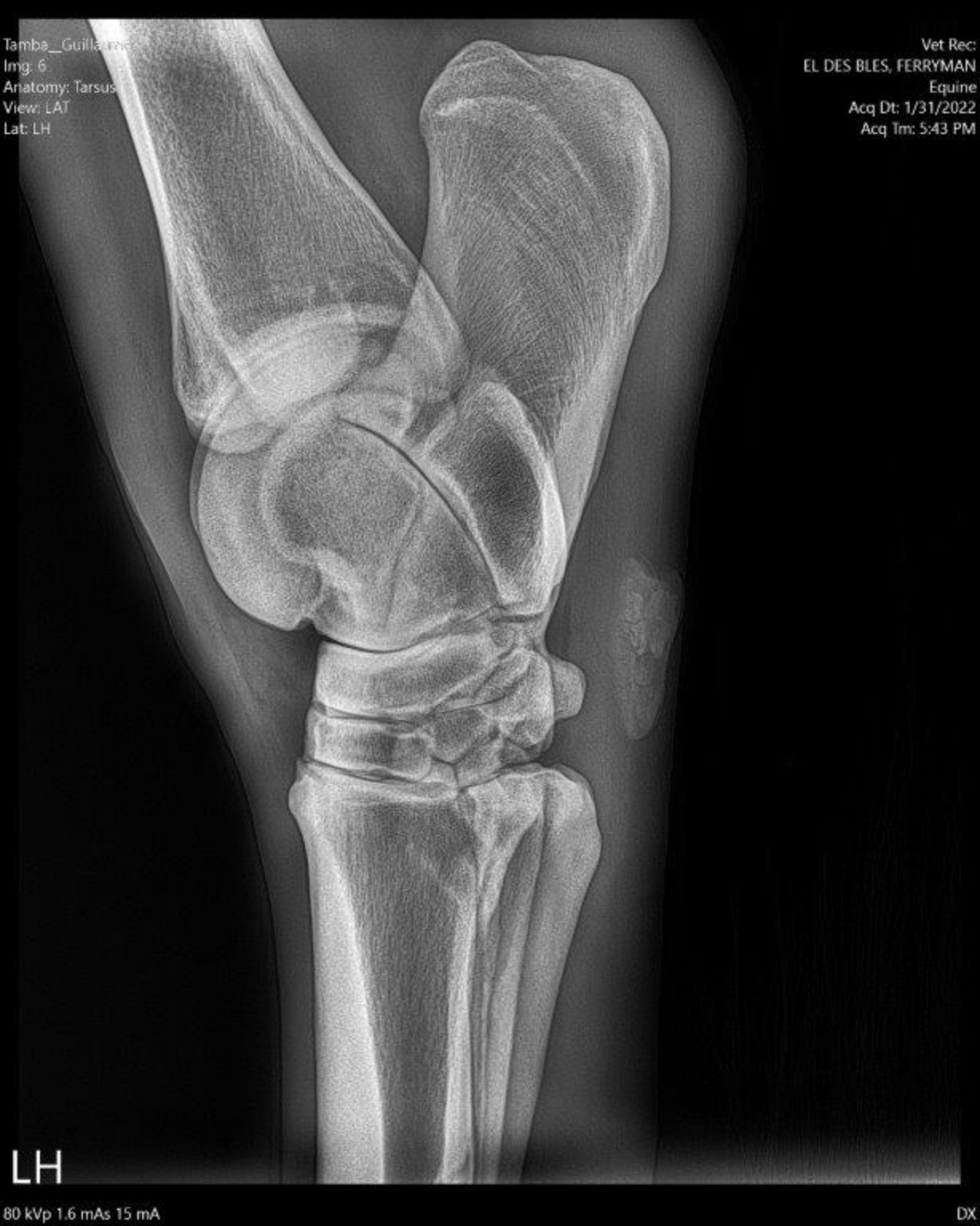Tamba_Guillaume
Img: 6
Anatomy: Tarsus
View: LAT
Lat: LH

Vet Rec:
EL DES BLES, FERRYMAN
Equine
Acq Dt: 1/31/2022
Acq Tm: 5:43 PM

LH

80 kVp 1.6 mAs 15 mA

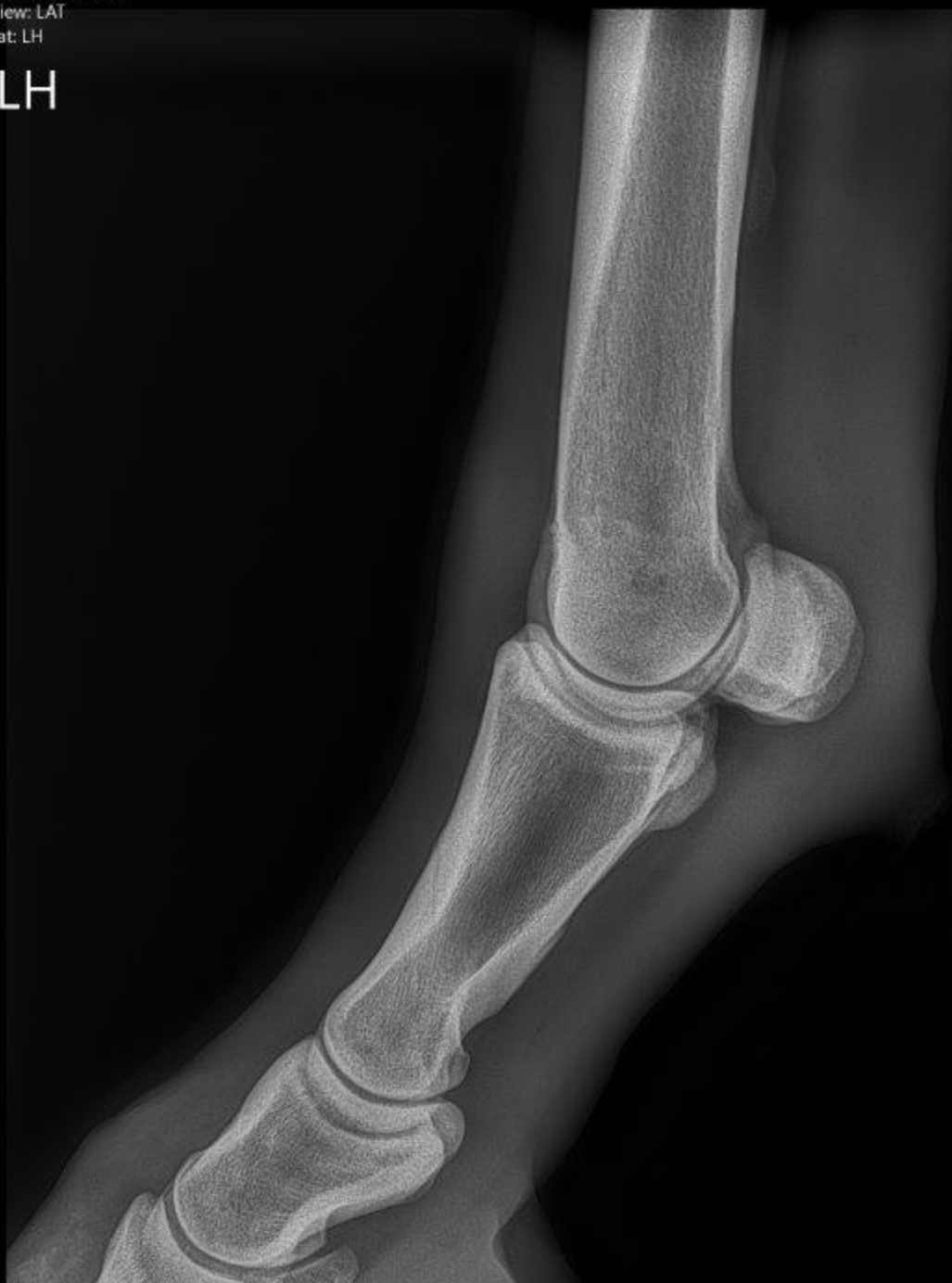DX



Tamba_Guillaume
Img: 5
Anatomy: Fetlock
View: LAT
Lat: LH

Vet Rec:
EL DES BLES, FERRYMAN
Equine
Acq Dt: 1/31/2022
Acq Tm: 5:42 PM

LH



Tamba_Guillaume
Img: 4
Anatomy: Fetlock
View: JIP
Lat: L

Vet Rec:
EL DES BLES, FERRYMAN
Equine
Acq Dt: 1/31/2022
Acq Tm: 5:42 PM

LF

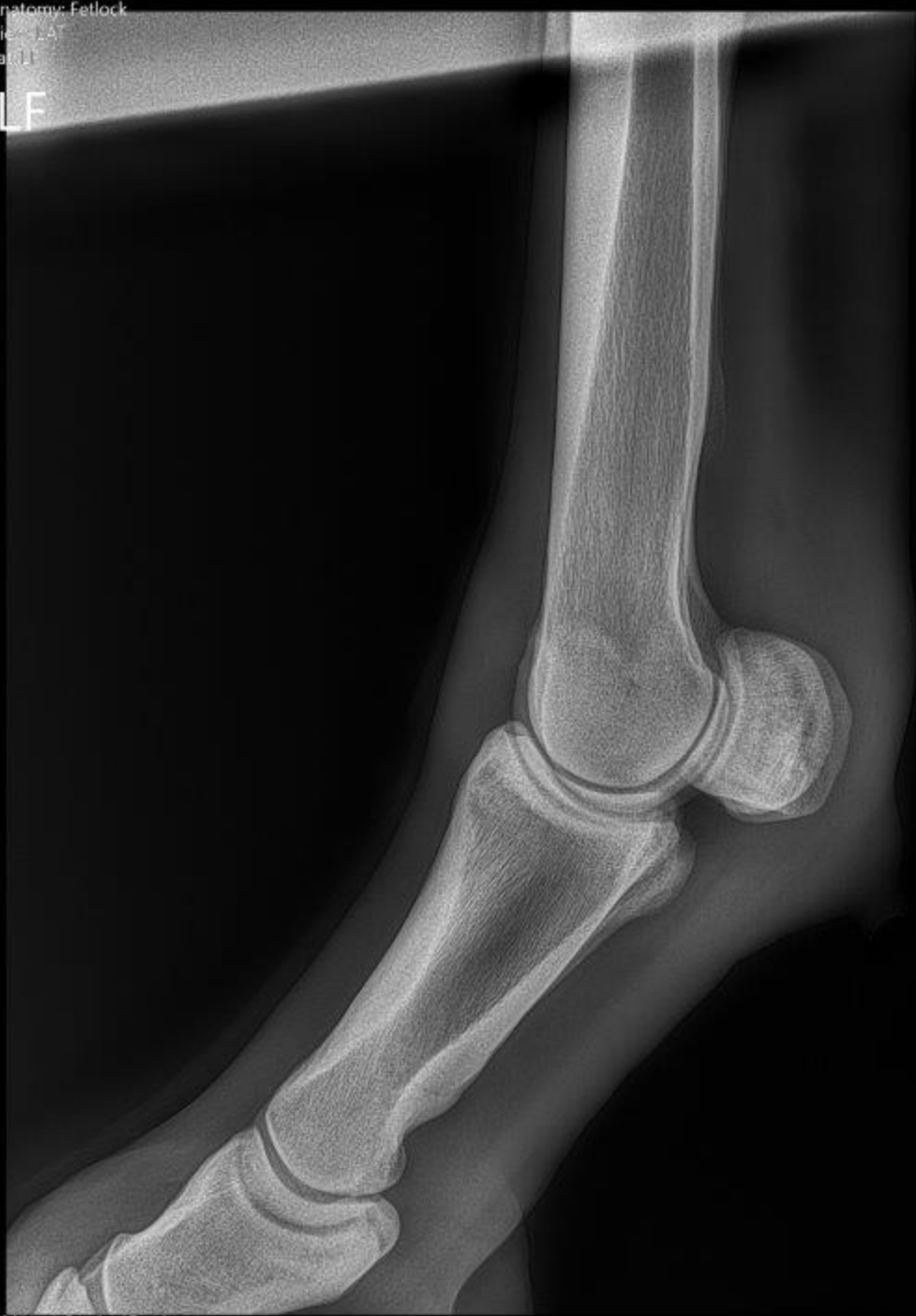L



Tamba_Guillaume
Img: 3
Anatomy: Fetlock
View: LAT
Lax: 11

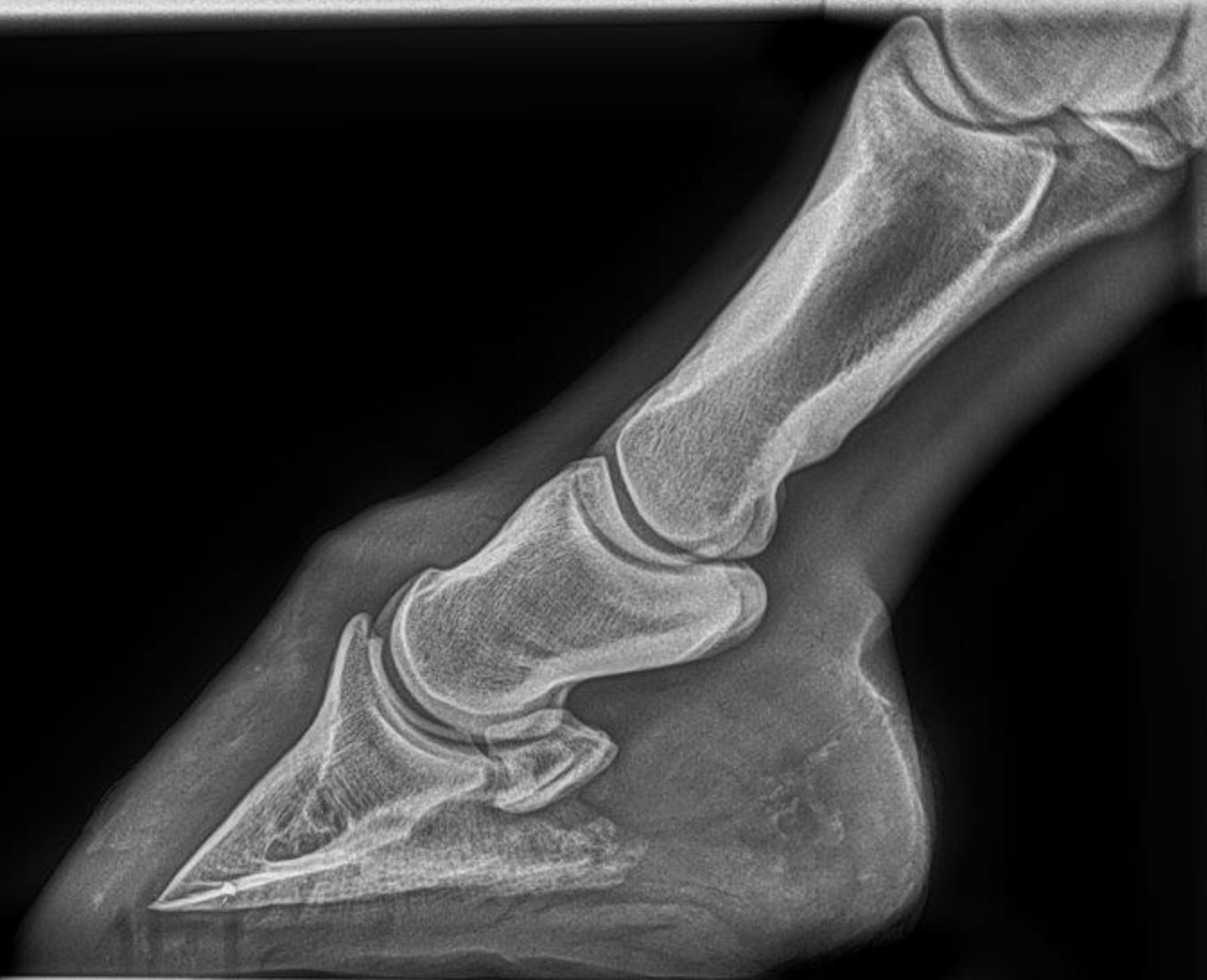Vet Rec:
EL DES BLES, FERRYMAN
Equine
Acq Dt: 1/31/2022
Acq Tm: 5:42 PM

LF



Series: Caudal
Image: 2
Anatomy: Foot
View: LAT
Link: LF

Study:
ELLESBLES, FERRYMAN
Equine
Acq Dt: 1/31/2022
Acq Tm: 5:41 PM



Tamba_Guillaume
Img: 1
Anatomy: Navicular
View: DP
Lat: LF

Vet Rec:
EL DES BLES, FERRYMAN
Equine
Acq Dt: 1/31/2022
Acq Tm: 5:41 PM

